



ROLE OF DIAGNOSTIC HYSTEROSCOPY IN INFERTILITY

KEY WORDS: Hysteroscopy, Laparoscopy, abnormalities, Primary, and secondary infertility

Dr Snehlata Dubey

MBBS, MS, OBGY, FMAS, FART, DGE, HOD Department of OBGY, BIMR Hospitals, Gwalior

ABSTRACT

Background: Infertility has become nowadays not only a medical, but a social problem as well. None of the laboratory findings alone is conclusive in diagnosing infertility. Diagnostic hysteroscopy is an accurate method of assessing and treating infertility. It is well known that hysteroscopy helps to improve reproductive outcomes by treating intrauterine pathologies. **Methods:** A retrospective hospital based study was carried out in two Hospital, (BIMR hospital, Gwalior and Peetambara Hospital, Gwalior) over a period of 4 years from 2018 to 2022. Hysteroscopy was done in 400 patients. Women aged 20-40 years with normal hormone profile without male factor infertility were included. **Results:** Out of 400 cases, 216 (54%) patients had primary infertility whereas 46% shows secondary infertility. Hysteroscopy detected abnormalities in 26.85% of the cases, out of which 17.59% showed acquired pathologies and 9.25% were congenital. The most common abnormalities were endometritis, intrauterine septum, fibroid and intrauterine adhesions. **Conclusions:** Hysteroscopy is an effective diagnostic tool for evaluation of certain significant and correctable tubo-peritoneal and intrauterine pathologies which are usually missed by other imaging modalities.

INTRODUCTION

Infertility is defined as the failure to establish a clinical pregnancy after 12 months of regular, unprotected sexual intercourse, due to an impairment of an individual's capacity to reproduce either alone or with his or her partner (1). Infertility is a clinical problem that affects 13% to 15% of couples worldwide (2).

Infertility affects about 10-15% of reproductive age couples(3). WHO estimates that 60 to 80 million couples worldwide currently suffer from infertility(4). Incidence of female infertility is 45.67%, male infertility is 54.33% and may be both can get involved in some of cases, range varies from region to region(5).

Total infertility is divided into primary and secondary infertility. Definitions of primary infertility by WHO, defines as "Inability to conceive within 12 months of exposure to pregnancy (i.e. Sexually active, non-contracepting and non-lactating) among women 15 to 49 years old"(6). Secondary infertility refers to the inability to conceive following a previous pregnancy. Globally, most infertile couples suffer from primary infertility(7). Though ultrasound and other laboratory investigations are necessary, the ability to see and manipulate the uterus, fallopian tubes, and ovaries during laparoscopy has made it an essential part of infertility evaluation (8). Similarly, visualising the uterine cavity and identifying the possible pathology has made hysteroscopy an equally important tool in infertility evaluation and uterine cavity abnormalities can all be resolved with accuracy at one session.

Hysteroscopy is the gold-standard test for assessing intrauterine conditions (9). Hysteroscopy can be used to directly and accurately diagnose abnormalities such as intrauterine adhesions, endometrial polyps, submucosal fibroids, endometritis, or uterine structural abnormalities through visualization of the cervical and intrauterine conditions, as well as through concurrent therapeutic interventions when necessary. In addition, hysteroscopy is advantageous as it can be used to perform biopsies (10). Treating intrauterine pathologies through hysteroscopy has been found to lead to improvements in reproductive outcomes, since intrauterine lesions can negatively affect the implantation rate (11). The benefits of using interventional hysteroscopy to treat intrauterine pathologies have been clearly documented in many studies (12). Additionally, hysteroscopic guided biopsy and therapeutic procedures like polypectomy, myomectomy, septal resection, and adhesiolysis can be done in the same sitting.

MATERIAL AND METHODS

This prospective study of 400 cases was conducted in 2 Hospitals, (BIMR hospital, Gwalior and Peetambara Hospital, Gwalior) over a period of 4 years from 2018 to 2022. Male partner's seminal fluid examination was done and was normal. Ultrasound and basic investigations were done and normal. After taking written and informed consent, hysteroscopy was performed during the post-menstrual phase on 7th, 8th and 9th day of cycle, using a 2.3-mm diameter continuous-flow endoscope. Distention of the uterine cavity was accomplished with normal saline solution. The hysteroscope was introduced into the cervical canal under vision. The procedure was considered complete only when the entire uterine cavity and both tubal ostia were visualized. Pelvic organs were examined and then whole peritoneal cavity was examined. The instruments used were those of KARL STORZ, Tuttlingen, Germany.

Hysteroscopy was performed to look for and evaluate the presence of intrauterine abnormalities (13). At the end of the hysteroscopy, under direct vision, an endometrial biopsy sample was obtained for histologic examination when indicated.

RESULTS

Out of 400 patients, 216 (54%) women had primary infertility and the rest (46%) had secondary infertility. Hysteroscopy detected abnormalities in 26.85% of the cases, out of which 17.59% showed acquired pathologies and 9.25% were congenital. Together, diagnostic hysteroscopy detected abnormalities in 20% of the infertile patients in both groups. The most common hysteroscopy abnormalities were endometritis (6.48%) (5.43%), polyp (fig 1) (3.70%) (4.34%) intrauterine septum (6.48% & 4.34%) fibroid (fig 2) (2.77) (6.52) and intrauterine adhesions (1.85%) (4.34%) in primary and secondary infertile patients respectively (Table 1). The prevalence of unilateral and bilateral tubal block was equal in both the groups. 5.5% patients developed minor complications (Table 2), of which gaseous distension of the abdomen (8%) was the most common. There was no major surgical or anaesthetic complication in any of the patients.

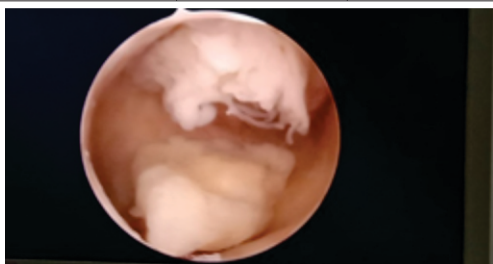
Among women with primary infertility, intrauterine pathologies were diagnosed in 216 (54%). These pathologies were divided into acquired findings diagnosed in 38 women (17.59%) and congenital malformations found in 20 women (9.25%).

Considering the group with secondary infertility, intrauterine pathologies were diagnosed in 64 women (34.78%). Of these,

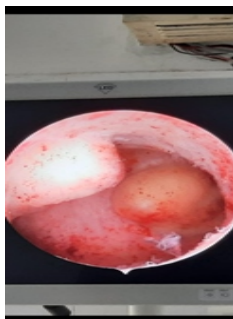
42 (22.82%) had acquired findings, and 22 (11.95%) were diagnosed with congenital uterine malformations. A significantly higher rate of patients with submucous fibroids and a significantly higher rate of patients with arcuate uterus were found in the group with secondary infertility.

Table showing various findings in primary and secondary infertility with complications of procedure

Findings	Primary infertility (number and %)	Secondary infertility (no and %)
Abnormal uterine findings	58 (26.85)	64 (34.78)
Acquired	38 (17.59 %)	42 (22.82%)
Fibroid	6(2.77)	12 (6.52)
Endometrial polyps	8 (3.70)	8 (4.34)
intrauterine adhesions	4 (1.85)	8 (4.34)
Cervical polyps	0	0
Endometritis	14 (6.48)	10 (5.43)
Tubal pathology	4(1.85)	4 (2.17)
Foreign body	2 (0.92)	0
Congenital	20 (9.25 %)	22 (11.95%)
Arcuate uterus	4 (1.85)	12 (6.52)
Unicornuate uterus	2 (0.92)	2 (1.08)
Bicornuate uterus(septum)	14 (6.48)	8 (4.34)
T- shaped uterus	0	0
Normal uterine findings	158(73.14)	120(65.21)
Total	108	92
Complications	Number	Percentage
Uterine perforation	4	1
Gaseous distension of abdomen	32	8
Bleeding	8	2
Total	44	5.5



Polyp (fig 1)



Fibroid (fig 2)

DISCUSSION

One of the basic steps of an infertility workup is to evaluate the shape and regularity of the uterine cavity (13). Acquired uterine lesions, such as uterine fibroids, endometrial polyps, intrauterine adhesions, or all of these, may cause infertility by interfering with proper embryo implantation and growth (14). Congenital uterine malformations are also thought to play a

role in delaying natural conception (15).Hysteroscopy has been proved to be the definite method for evaluation of the uterine cavity and diagnosis of associated abnormalities (13,16). Several studies have demonstrated that once the uterine cavity has to be investigated as part of the infertility workup, hysteroscopy is much more accurate than other diagnostic methods, mainly HSG (17). Based on the results of the previous studies, it appears that more than 1/3 of the patients interpreted as normal following HSG are found to have a uterine abnormality after diagnostic hysteroscopy, which might be a significant cause of reproductive failure. These women may be wrongly treated, or unnecessarily investigated, while their intrauterine lesion has been missed (13).

Other than septate uterus, the major hysteroscopic abnormalities in our study were fibroids and polyps similar to another study (18).The evidence to suggest that fibroids decrease fertility is inferential and relatively weak (19).

No significant difference was found in the rate of intrauterine adhesions comparing the patients with primary versus secondary infertility, in spite of the known relationship between secondary infertility and the existence of adhesions, being mostly the result of uterine curettage for postpartum or postabortion residua. Oliveira (20) also found intrauterine adhesions in 10% of patients with repeated failed IVF cycles of whom none had undergone previous abortions or other uterine manipulation.

While debating the need for routine diagnostic hysteroscopy in the evaluation of the infertile woman, one must keep in mind that this procedure today is no longer a complicated “in-patient-general-anaesthesia one,” but rather a simple, fast, outpatient procedure, requiring short training with high success rates.

CONCLUSIONS

Diagnostic hysteroscopy is an effective and safe tool in comprehensive evaluation of infertility, particularly for detecting acquired and congenital causes of infertility. These are correctable abnormalities that are unfortunately missed by routine pelvic examination and usual imaging procedures.

REFERENCES

1. Zegers-Hochschild F, Adamson GD, Dyer S, Racowsky C, de Mouzon J, Sokol R, et al. The International Glossary on Infertility and Fertility Care, 2017. *Hum Reprod.* 2017;32(9):1786-1801.
2. Kamel RM. Management of the infertile couple: an evidence-based protocol. *ReprodBiol Endocrinol.* 2010;8:21.
3. Boivin J, Bunting L, Collins JA, Nygren KG. International estimates of infertility prevalence and treatment-seeking: Potential need and demand for infertility medical care. *Hum Reprod.* 2007;22:1506-12.
4. World Health Organization. Infecundity, infertility, and childlessness in developing countries. *DHS Comparative Reports No 9.* Calverton, Maryland, USA: ORC Macro and the World Health Organization; 2004.
5. ShamilaS, SasikalaSL. Primary Report on the Risk Factors Affecting Female Infertility in South Indian Districts of Tamil Nadu and Kerala. *Indian J Community Med.* 2011;36(1):59-61.
6. Reproductive health indicators for global monitoring: Report of the second interagency meeting, 2001. Geneva: World Health Organization; 2001: 23.
7. Inhorn MC. Global infertility and the globalization of new reproductive technologies: illustrations from Egypt. *Soc Sci Med.* 2003;56:1837-51.
8. Fatum M, Laufer N, Simon A. Investigation of the infertile couple: should diagnostic laparoscopy be performed after normal hysterosalpin gography in treating infertility suspected to be of unknown origin? *Hum Reprod.* 2002;17(1):1-3.
9. Pundir J, El Toukhy T. Uterine cavity assessment prior to IVF. *Womens Health (Lond).* 2010;6(6):841-848.
10. Pundir J, Pundir V, Omanwa K, KhalafY, El-Toukhy T. Hysteroscopy prior to the first IVF cycle: a systematic review and meta-analysis. *Reprod Biomed Online.* 2014;28(2):151-161.
11. RudicBiljic-Erski I, Vasiljevic V, Rakic S, Mihajlovic S, Smiljkovic OD. The impact of hysteroscopic myomectomy on fertility and pregnancy outcomes of infertile women according characteristics of submucous fibroids. *Clin Exp Obstet Gynecol.* 2019;46(2):235-240.
12. Wang X, Hou H, Yu Q. Fertility and pregnancy outcomes following hysteroscopic metroplasty of different sized uterine septa: a retrospective cohort study protocol. *Medicine (Baltimore).* 2019;98(30):e16623.
13. Shushan A, Rojansky N. Should hysteroscopy be a part of the basic infertility workup? *Hum Reprod.* 1999; 14 (8): 1923-1924.

14. Brown SE, Coddington CC, Schnorr J, Toner JP, Gibbons W, Oehninger S. Evaluation of outpatient hysteroscopy, saline infusion hysterosonography and hysterosalpingography in infertile women: a prospective, randomized study. *FertilSteril*. 2000;74:1029–1034 .
15. Grimbizis GF, Camus M, Tarlatzis BS, Bontis JN, Devroey P. Clinical implications of uterine malformations and hysteroscopic treatment results. *Hum Reprod Update*. 2001;7 (1): 161–174 .
16. American Society for Reproductive Medicine Optimal evaluation of the infertile female— committee opinion. Birmingham, AL: American Society for Reproductive Medicine; June 2000 .
17. Kessler I, Lancet M. Hysterography and hysteroscopy: a comparison. *FertilSteril*. 1986;46 (4):709–710 .
18. Nagele F, O'Connor H, Davies A, Badawy A, Mohamed H, Magos A. 2500 outpatient diagnostic hysteroscopies. *Obstet Gynecol*. 1996;88:87–92
19. Kamiński P, Wieczorek K, Marianowski L. Usefulness of hysteroscopy in diagnosing sterility. *Ginek Pol*. 1992;63:634-7.
20. Oliveira FG, Abdelmassih VG, Diamond MP, Dozortsev D, Nagy ZP, Abdelmassih R. Uterine cavity findings and hysteroscopic interventions in patients undergoing in vitro fertilization- embryo transfer who repeatedly cannot conceive. *FertilSteril*. 2003;80 (6): 1371– 1375 .